

Secondary Rhinoplasty

175

Stephen W. Perkins **Shervin Naderi**

Despite new cosmetic procedures and techniques developed throughout the last several decades, rhinoplasty remains one of the most challenging and rewarding surgeries performed by facial plastic surgeons. It is an operation that can dramatically alter the appearance of a patient and detract from the undue attention the nose draws in the center of the face. With good results, it can bestow confidence on young and old alike. With poor outcome, the patient can become withdrawn, self-conscious, and even depressed. It remains one of the most common cosmetic procedures sought by both men and women. It is an operation done on almost all age groups and walks of life.

Rhinoplasty is an operation that takes years to learn well and a lifetime to attempt to perfect. Its aesthetic and functional outcomes go hand in hand, which must be well understood by the surgeon to result in a happy patient. The progressively evolving surgical result must be closely studied even years later to witness and learn from surgical decisions and maneuvers made pre- and intraoperatively. The "Gunter-like" diagram is a valuable tool in this self-evaluation and self-improvement by each surgeon.

Proper aesthetic facial analysis provides the first challenge to the rhinoplasty surgeon. In an operation where millimeters determine outcome, the ideal surgical result relies on appropriate presurgical planning. The second challenge for the rhinoplasty surgeon is the three-dimensional aspect of the nasal bony and cartilaginous architecture. Each surgical maneuver aimed at manipulating a certain view of the nose results in changes in multiple other nasal views as well. The soft tissue envelope and its "shrink wrapping" over time provide the third and most unpredictable challenge to the rhinoplasty surgeon. Although traditionally the 1-year postoperative result is deemed the rhinoplasty's final result by surgeons and patients, because of the continual soft tissue changes over time, the final results must be reevaluated even 10 to 20 or more years later.

These factors are what a rhinoplasty surgeon considers when operating on a "virgin" or primary nose. Because of a variety of reasons, however, a surgeon may need to operate on a nose that has been operated on previously, either by the same surgeon or another. Often, this is the third or fourth operation, making the term "revision rhinoplasty" possibly more descriptive than the commonly used term, "secondary rhinoplasty." A variety of reasons contribute to the need for revision rhinoplasty. These include, but are not limited to, poor surgical planning, improper technique, underresection, or, more commonly, overzealous reduction rhinoplasty, very thick or very thin nasal soft tissue envelope, insufficient nasal framework, unpredictable healing, inadequate surgeon and patient preoperative communication, unrealistic patient expectations, or traumatic injury to the previously operated nose.

Revision rhinoplasty introduces a new series of challenges for the facial plastic surgeon. Variable degree of scarring, loss of nasal support mechanisms because of aggressive reduction rhinoplasty, and lack of adequate septal cartilage for rebuilding are only some of the obstacles a surgeon can face venturing back into a previously operated nose. The use of auricular cartilage or other suitable building blocks [e.g., rib cartilage, irradiated cartilage, GORE S.A.M. (Gore-Tex subcutaneous augmentation material), AlloDerm (or other acellular tissue) and other alternatives to autogenous septal cartilage) are also more common than in primary rhinoplasty. Even in secondary rhinoplasty, however, allografts should be used as an alternative rather than a substitute for the more preferential autografts (1). A graft material not commonly used but worth consideration is an autologous dermal graft, especially for patients concerned about the potential of prions and other small infectious particles possibly associated with cadaveric tissue (3).

Preoperative planning, including in-office patient examination and counseling, is a crucial investment of time. We cannot stress the importance of "imaging" enough. This is

an opportunity for the surgeon and patient to visually communicate their respective goals for the operation. This technology also allows the surgeon to show the possible limitations of the operation with respect to each patient's anatomy through the use of morphing software. The office consult also provides a forum for the discussion of possible implant choices. The recovery room is not the ideal place to inform a patient that he or she now has a foreign or cadaveric implant if this possibility had not been previously addressed with the patient. Yet each patient has to be aware that it is usually after entering the nose that the surgeon can properly evaluate what was previously done and what further needs to be done to correct the problem. The columellar incision must also be mentioned to the patient. Frequently, major revisions, especially of the lobule, necessitate an external approach, whereas other problems can be approached through an endonasal technique for pocket grafting, alar retraction correction, or dorsal refinement.

The problems requiring revision rhinoplasty can be categorized in relation to the anatomic site as well as the types of aesthetic and functional defects commonly seen. Common areas to address include the pyramid, lobule, and airway. Most of these issues can be attributed to errors of omission or errors of commission. We define errors of omission as those maneuvers that needed to be done and were not done in the previous surgery. On the contrary, errors of commission are those maneuvers that were not necessary in the previous surgery or were done too aggressively, leaving the nose usually destabilized with an overoperated appearance. In this chapter, we present the most common reasons for revision rhinoplasty in our practice and offer some time-tested solutions.

ERRORS OF OMISSION

Errors of omission most commonly include inadequate tip refinement, dorsal hump reduction, or pyramid narrowing. A nose that is still overprojected or underrotated is yet another example of this error. These problems are easy to address and require completion of the maneuvers that were either done too conservatively in the previous operation or not done at all (Fig. 175.1).

Here and elsewhere throughout this chapter is noted that the first step in correction of any nasal deformity, whether primary or revision is the appropriate diagnosis of the internal structural variations leading to the external aesthetic or functional abnormality. As in any area of medicine and surgery, diagnosis is the initial crucial step. The good rhinoplasty surgeon studies each nose, diagnoses the problem, and offers a tailored solution. Much too frequently, surgeons learn a "standard" rhinoplasty operation and apply the same series of maneuvers to each nose, regardless of the problem at hand and the subtle individual variations in anatomy. Without the appropriate diagnosis, the proper surgery cannot be carried out.

The Overprojected Tip

Multiple causes of an overprojected tip exist and, hence, multiple techniques for addressing this problem. These include excess length of the caudal septum, long lower lateral cartilages, a "hanging" or underrotated tip giving the appearance of overprojection, and previously excessive augmentative use of tip grafts. It is crucial to realize the aesthetic relationship between tip projection and rotation and how each surgical maneuver can affect one or both. Our first choice for deprojection is a complete transfixation incision to disrupt nasal tip support mechanisms. The second maneuver would be appropriate resection of the caudal septum. If further deprojection is needed, the Lipsett technique is used and we use 6.0 polydioxanone (PDS) for this purpose. This technique involves transection of the medial crus of the lower lateral cartilage somewhere between its upper and middle third followed by overlapping and suturing to shorten the medial crus of the lower lateral cartilage. In addition to deprojection, this maneuver also creates derotation. Although usually done bilaterally, the Lipsett technique can be done unilaterally to correct tip asymmetries. The original description by Lipsett (3) did not include suture stabilization, but given the contracture caused by healing, we believe suturing allows for more predictable results.

The Underrotated Tip

To increase tip rotation, an inverted triangular wedge of caudal septum can be resected. This will also decrease projection, as hinted above, and must be taken into account. Lateral crural flap is also a useful technique, which provides deprojection as well as rotation. This technique involves elevation of vestibular skin and mucosa at the lateral crus of the lower lateral cartilage somewhere between the middle and lateral third followed by division, overlay, and suture stabilization using 5.0 Monocryl. Our technique is a modification of the one described by Kridel in 1991 (4).

Furthermore, it is important to understand that cephalic trim allows for rotation, which is enhanced by domal sutures. Proper placement of a columellar strut also pushes on the medial crus of the lower lateral cartilages and enhances rotation as well as providing support to the tip. More dramatic tip rotation can be achieved by releasing connections between the lower lateral cartilages (LLC) and the caudal and dorsal septum and resuturing the LLC in a more rotated position.

ERRORS OF COMMISSION

Errors of commission are the more common problems encountered in our practice. It is not uncommon to find a mixture of problems that combine errors of omission and

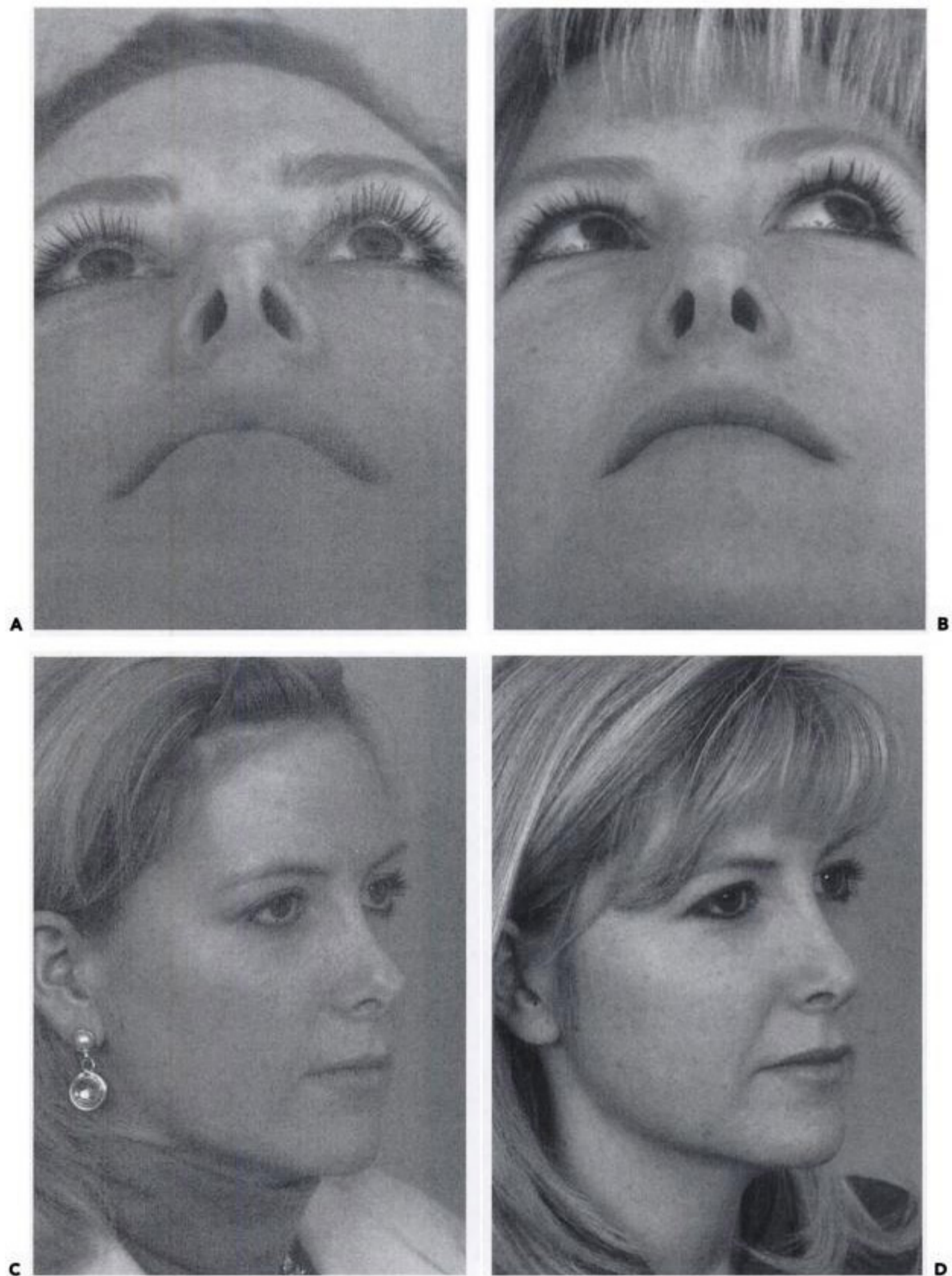

Figure 175.3 A–H: Collapsed right midvault corrected with right spreader graft. Tip bosses with asymmetry corrected with conchal cartilage alar strut grafts and double layer tip graft. Alar retraction corrected with composite conchal cartilage grafts. Dorsal saddle-nose deformity corrected with cartilage onlay.

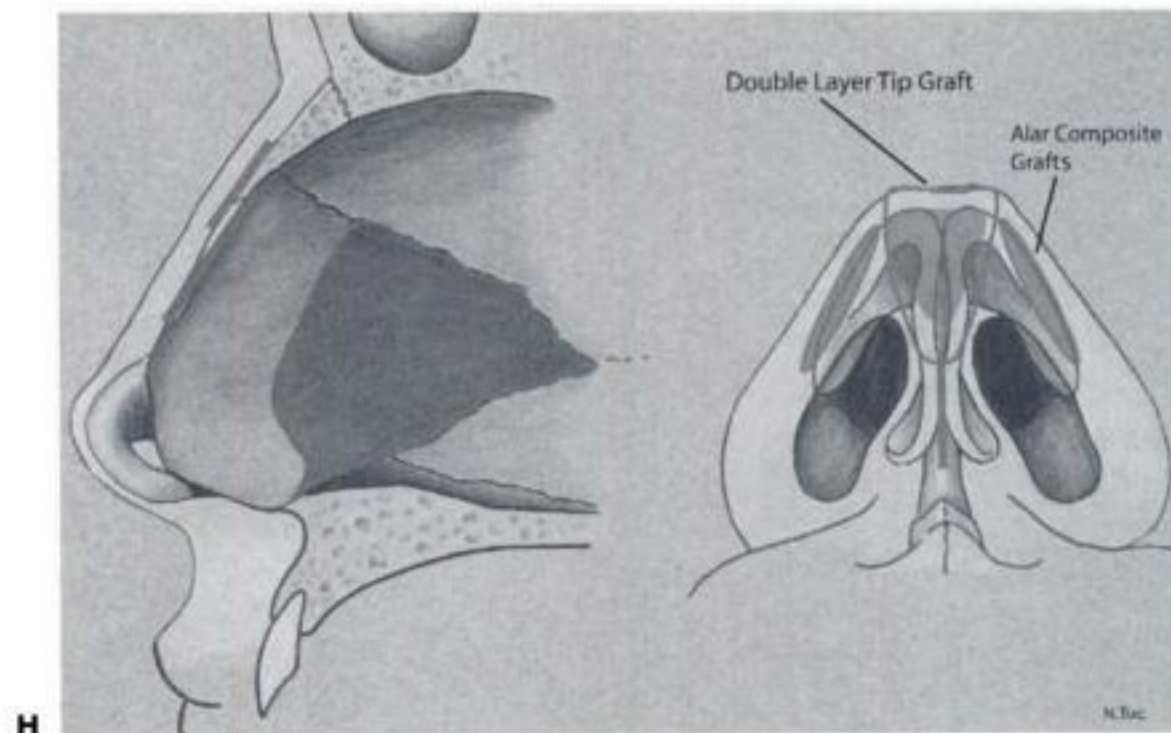
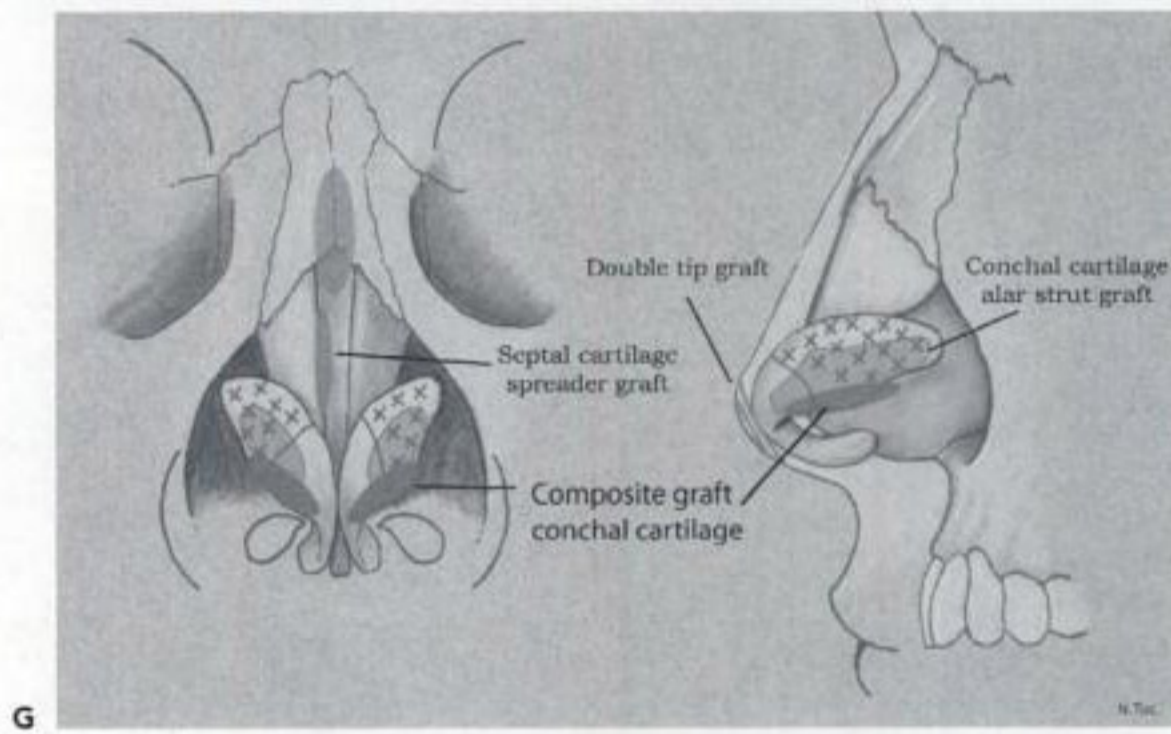


Figure 175.3 (continued)

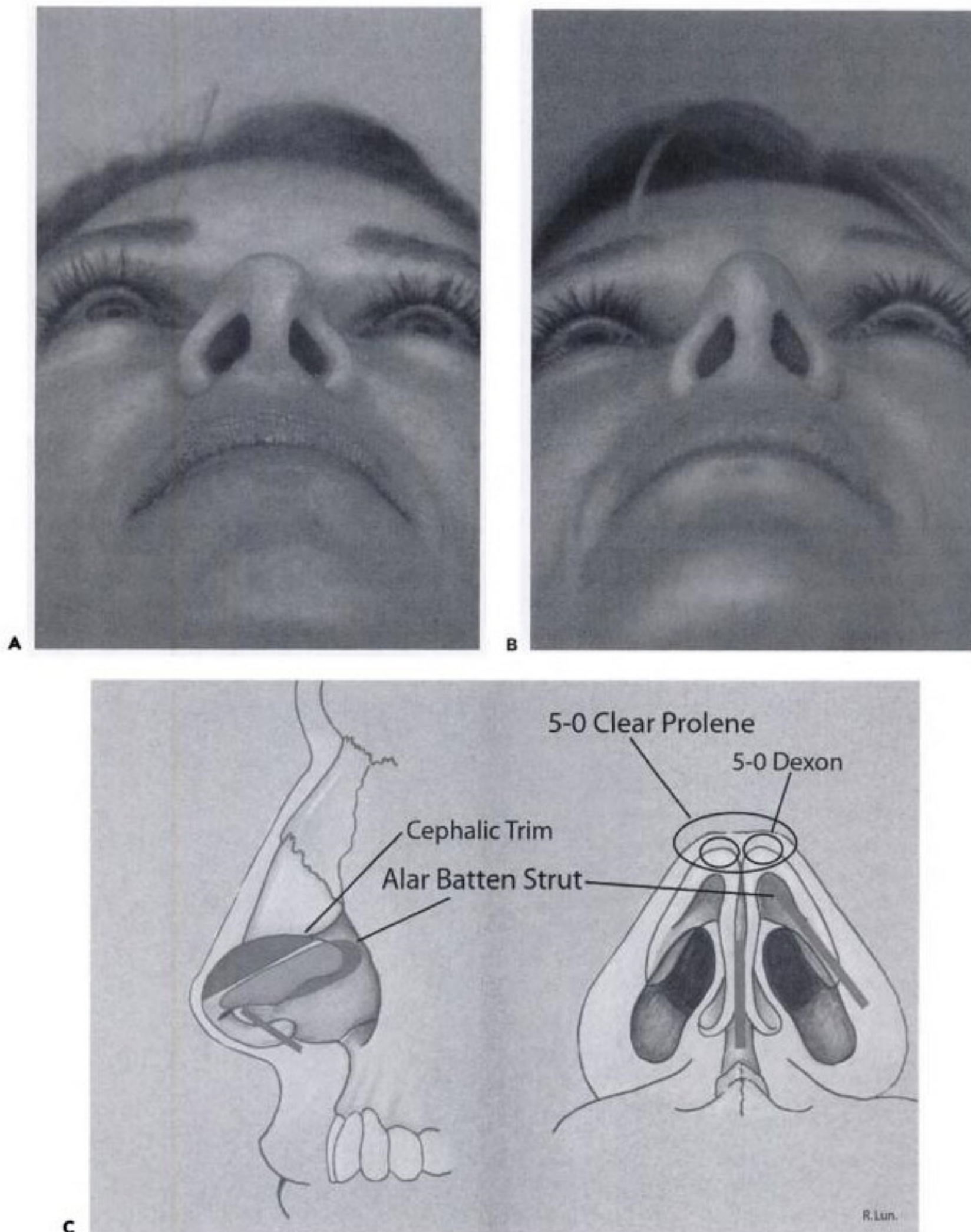


Figure 175.4 A–C: Errors of commission. Collapsed left ala caused by overresection of left lower lateral cartilage corrected with alar strut graft.

correction of the problem and aesthetic alignment of the dorsum in relation to tip and supratip height. In-office steroid injections may be necessary to reduce supratip scarring and hypertrophy (7).

The saddle nose will require augmentation with cartilage, alloplastic material, or both. Occasionally, the dorsal septum must also be augmented, especially in cases of excessive septal resection or septal necrosis. In severe cases, rib cartilage is

our preferred choice, although multiple layers of auricular cartilage wrapped in AlloDerm or Merselene mesh can also be used. Alternatively, GORE S.A.M. is an acceptable, easily available choice.

A more serious and more common pyramid abnormality, as mentioned earlier, is the "open roof" deformity caused by collapse or retractions of the upper lateral cartilages. This problem can be addressed with a variety of techniques, including the use of spreader grafts, dorsal onlay grafts, and osteotomies.

Our indication for the use of spreader grafts are (a) unilateral asymmetry with in-fracture or inward curvature of one upper lateral cartilage; (b) bilateral inward curvature of upper lateral cartilages with "hour glass" appearance; (c) extremely narrow pyramid with tall middorsal hump and thin skin; and (d) prevention of late contracture deformity at the upper lateral cartilage-bony junction.

Lobule Abnormalities

Some lobular problems can be addressed through an endonasal approach with precise pocket grafting. Other more severe abnormalities necessitate an external columellar approach.

Alar Collapse or Retraction

Alar collapse or retractions are caused by weakness of the ala secondary to lack of cartilaginous support or scaffolding in this area. In a patient presenting for revision rhinoplasty, this defect may have been congenital and unrecognized by the primary surgeon or iatrogenic as a result of the previous surgery. These defects can be corrected through an endonasal technique. For alar collapse, cartilage grafts can be placed through a marginal incision in a precise pocket as an alar batten (Fig. 175.4). This maneuver also helps with symptoms of nasal airway obstruction caused by external valve collapse. Alar retractions of significance require composite auricular cartilage grafts obtained through an anterior approach from the cymba concha and secured in place with 5.0 plain gut suture. Bolsters are not necessary. The harvested composite graft is placed on the vestibular side of the ala to replace missing or contracted vestibular skin or mucosa, as well as provide cartilaginous support at the point of maximal retraction. Our technique for graft harvest, which is similar to that described by Constantian (8), differs from his in that we are usually able to close the defect primarily by extending the incision at the concha cymba inferiorly along the antihelix with undermining of the concha skin enabling tension-free closure.

More severe alar collapse causing a "pinched" tip appearance usually results from buckling of the lateral alar crus, aggressive cephalic trims, lateral division or rim strips, or total removal of the lateral crus. These problems necessitate providing support in the form of alar strut grafts. These are placed underneath the lateral crus of the

lower lateral cartilages and in an open approach can be secured using absorbable sutures (Figs. 175.5 and 175.6). Alternatively, the graft can be the only cartilage in this area used to rebuild the lateral crus because of a total resection. The ultimate goal is a nasal base that is triangular in shape with good alar support.

Lobular Reconstruction and the "Short Nose"

Major lobular reconstruction is a challenging problem that requires an external columellar incision with careful study of the underlying problems. Problems to be addressed are asymmetries of tip and ala, unusual bosses, alar-columellar disproportions, rotation, and projection. A variety of reasons exist for the development of bosses and each problem needs to be evaluated fully and treatment individualized (9). Areas that need to be resolved often include loss of tip support, or tip underprojection or overrotation. Iatrogenic causes of a "short nose" include overresection of caudal septum, overshortening of upper lateral cartilages, overrotation or resection of alar cartilages, overresection of dorsum, loss of nasal septum, or stunt of growth from previous surgical maneuvers in younger patients.

If the nose is not overtaken by scar tissue and if adequate tip cartilage is in place, then techniques used in primary rhinoplasty can also be used here (e.g., lateral crural steal or modifications of the Goldman tip technique for tip projection) (10,11). These techniques involve borrowing cartilage from the more lateral portions of the lower lateral cartilages to augment the dome and provide enhanced projection. Often given the findings encountered in a revision nose such as hostile scar tissue and inadequate lower lateral cartilages, the best approach, however, is the "back-to-basics" approach. This involves rebuilding of the cartilaginous support scaffolding of the nose from the ground up (Fig. 175.6; Fig. 175.7). The rhinoplasty surgeon must be comfortable with nasal anatomy and be able to use septal, auricular, or rib cartilage in addition to other materials to recreate the tip architecture. Once the major support mechanisms are restored, fine-tuning can be done with a variety of grafts or minor reductive shaves or augmentative onlays and grafts. Dorsal augmentation, infratip lobule grafts, single- and double-layer shield grafts, "cap" grafts, Peck grafts, "blocking" grafts, and excision of posterior caudal septal angle, to name a few, are all techniques that must be learned well and considered in such situations. In more severe cases, the dynamic adjustable rotation tip (DART) technique with the use of spreader grafts or a dorsal onlay graft combined with a columellar strut in a cantilever technique may be a viable option (12) (Fig. 175.8). In yet more radical situations, the use of GORE S.A.M. and other synthetic material may be required. We do not use calvarial bone. Occasionally, in a severely retracted nose, the limiting factor will be the pliability of the skin and soft tissue envelope. In some cases, the surgeon can discuss with the patient the possible need for total nasal reconstruction with the use of paramedian forehead flaps.

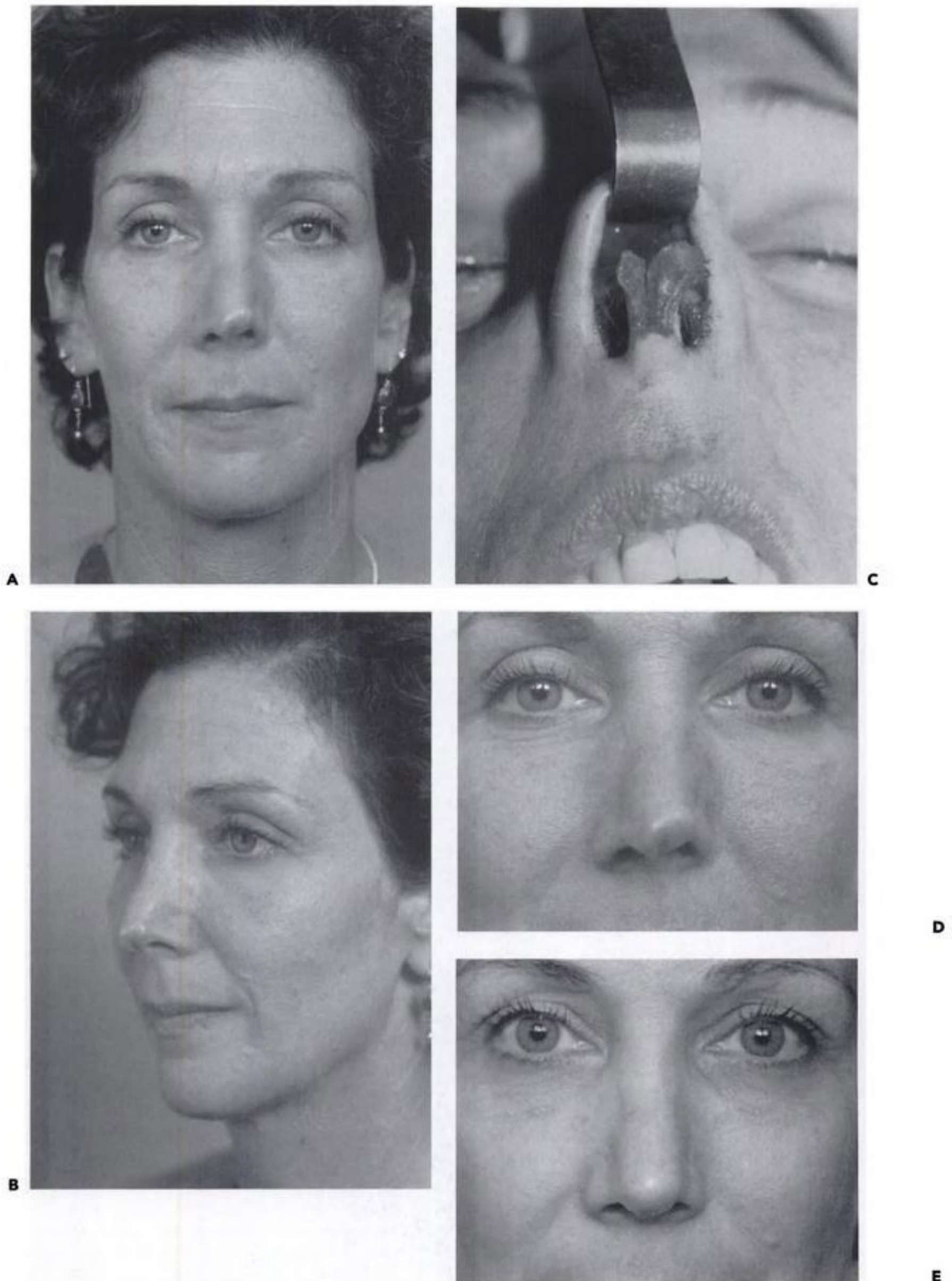

Figure 175.5 A–E: Severe tip asymmetry caused by overresection of lower lateral cartilages with dome division.

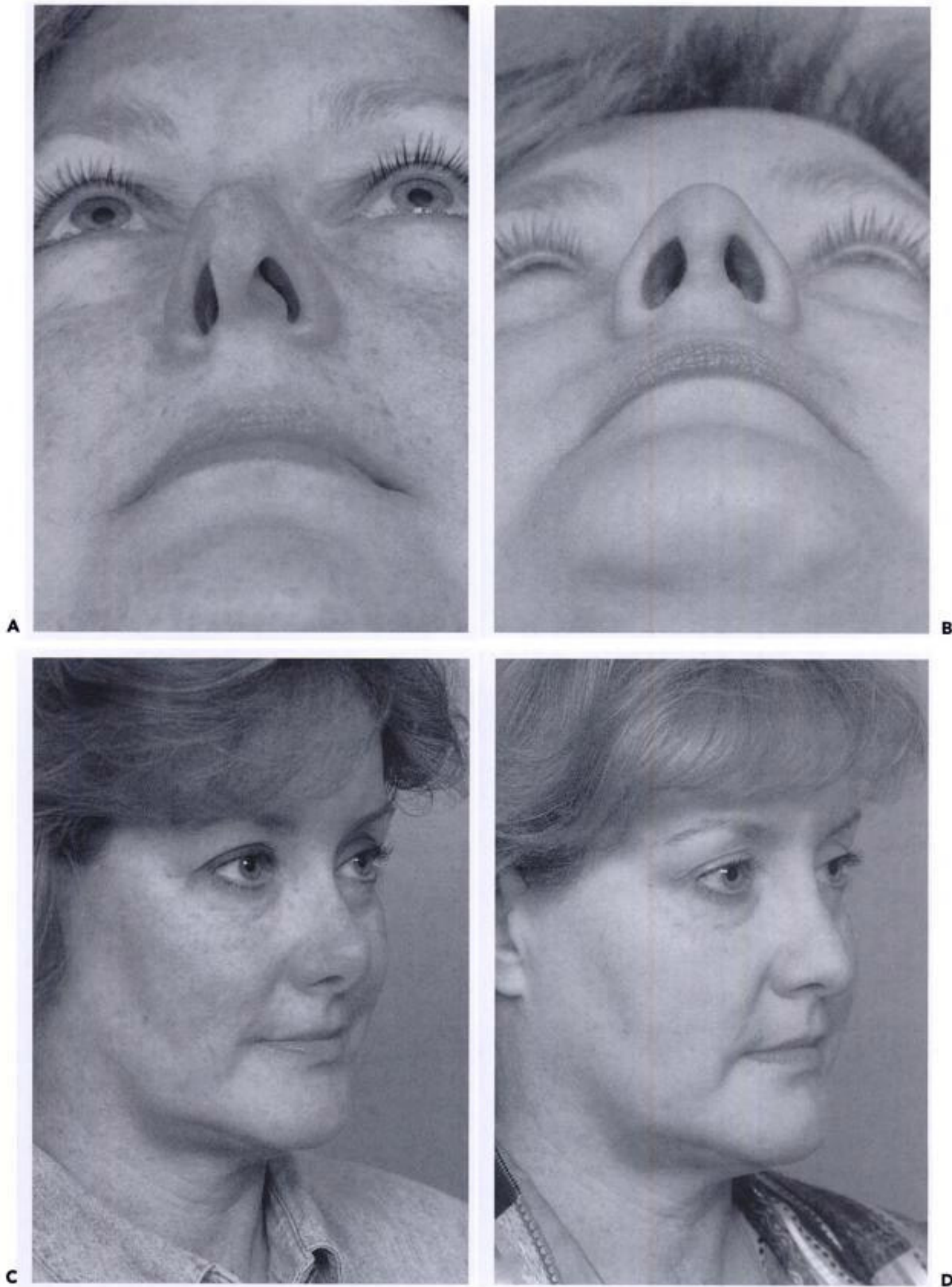

Figure 175.7 A–F: Complete lobular reconstruction with “back-to-basics” approach. Rebuilding the tip cartilages from the “ground up.” (continues)

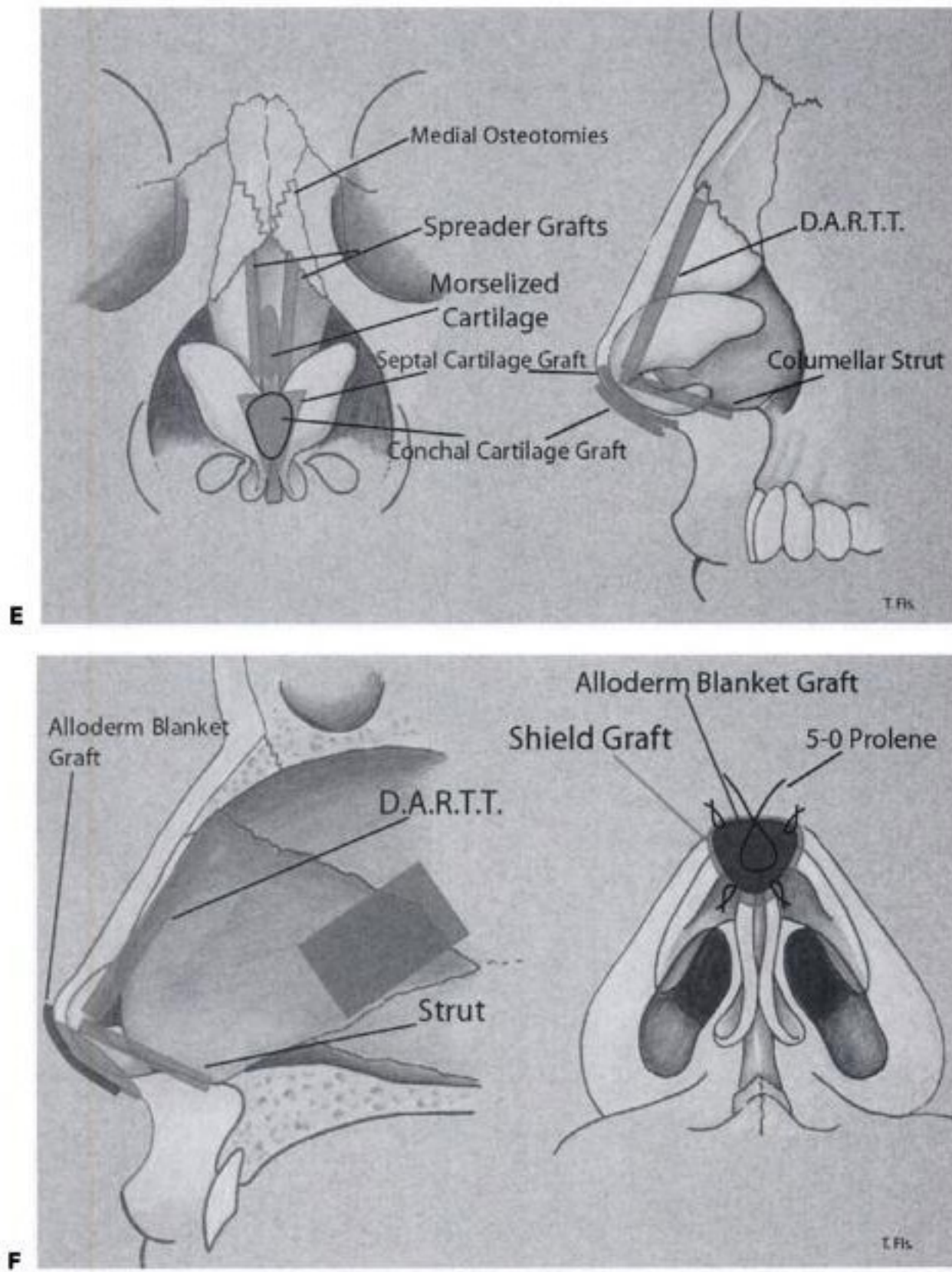


Figure 175.7 (continued)

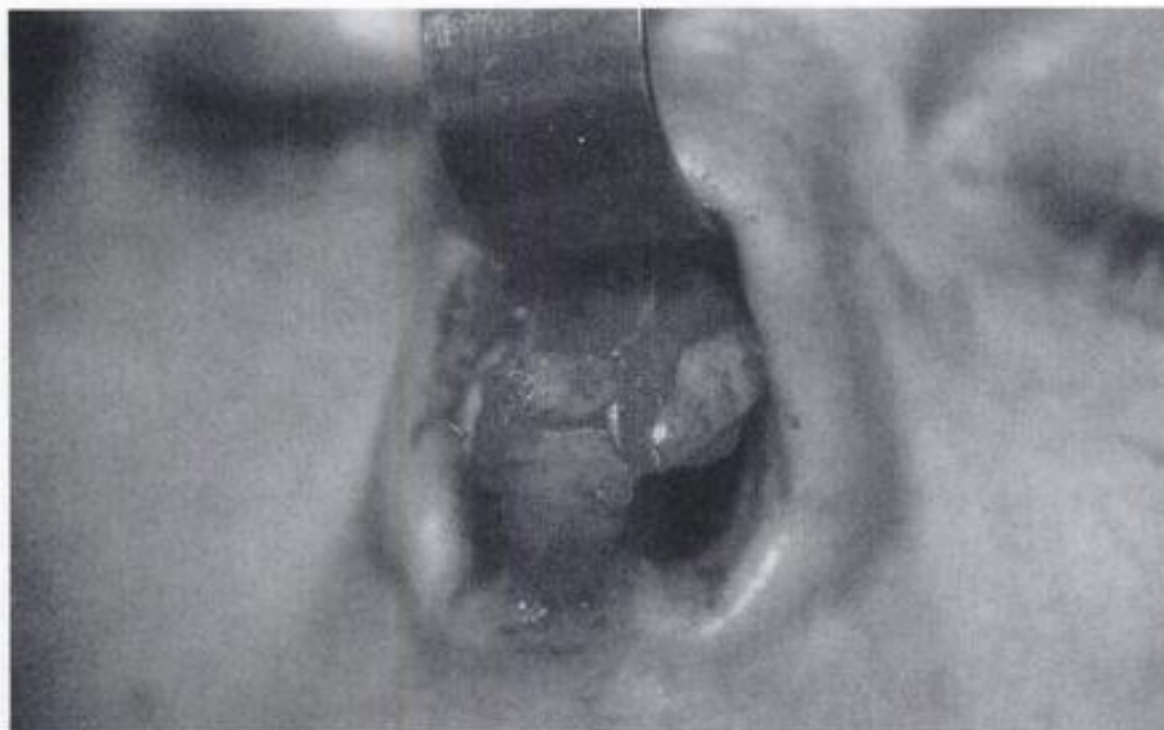

Figure 175.8 Short nose with overrotated tip, narrow dorsum, and tip asymmetry corrected with multiple grafts.

SUMMARY

Entering a previously operated nose brings with it a long list of challenges and the satisfaction of completing an often mentally taxing procedure. The first requirement for success is the proper diagnosis of the aesthetic and functional problem at hand. Minute cartilage, bony, and soft tissue asymmetries will show up down the line and will bother the patient and the surgeon and, hence, must be addressed intraoperatively. Although diagnosis is the first step, each surgeon must have a variety of techniques available to address each diagnosed problem. With such a combination approach and respect for the nasal tissue, good operative results can be expected.

Many of the techniques discussed here are commonly used in the complicated primary rhinoplasty as well. What each facial plastic surgeon must be able to rely on is the back-to-basics approach. When all else fails, do not be afraid to take the nose, the scar tissue, and whatever remnant cartilage apart and build from the ground up. This is the essence of being able to properly revise a previously operated nose.

Also, make all the minor adjustments needed as you see them at the time of the operation. Chances are if some minor detail bothered you during the case but you "let it go," with time and resolution of edema, this annoyance will be further highlighted and may distract you and the patient from appreciating an otherwise great surgical result.

HIGHLIGHTS

- Revision rhinoplasty is challenging surgery, and results are less predictable than in primary rhinoplasty.
- Successful revision rhinoplasty depends on an accurate and specific diagnosis using anatomic and aesthetic classification of the deformities.
- Bosses are knoblike irregularities of the tip cartilage that cause asymmetry. These deformities are corrected by shaving the cartilage on the more prominent side or by augmenting the cartilage on the deficient side to create a more pleasing appearance.
- Pinching is usually caused by overresection of the lateral crus of the lower lateral cartilage, causing nasal valve collapse and nasal obstruction. This is corrected by reinforcing the deficient area with a batten of auricular or septal cartilage.
- Alar retraction is usually caused by excessive resection of cartilage and vestibular skin. It is corrected using a composite graft of auricular cartilage and skin, replacing the "unrolled" vestibular skin, which then becomes part of the external nasal alar skin.

- Columellar retraction can be caused by congenital, traumatic, or surgical factors. The deficiency of caudal septal cartilage is replaced with septal or auricular cartilage or, if the membrane is also deficient, a composite skin-cartilage graft.
- Polly-beak deformity is excessive fullness of the supratip region. Correction of this deformity depends on accurate diagnosis of the cause and can include waiting for further scar remodeling, steroid injection, additional reduction of cartilaginous septum, removal of thick scar tissue, augmentation of the bony pyramid, or augmentation of the lower lateral cartilage.
- Midnasal asymmetry can be congenital but is commonly caused by traumatic subluxation of the attachment of the upper lateral cartilage to the nasal bone. Correction can be made by using a cartilage onlay graft to camouflage the asymmetric area of depression.
- Saddle-nose deformity is a concave appearance of the nasal dorsum. In postrhinoplasty patients, this is usually caused by overly aggressive resection of the bone or cartilage of the dorsum. Repair of this defect usually requires cartilage grafting.

REFERENCES

1. Rokade AV, Hughes K. Outcome of GORE-TEX implants in augmentation rhinoplasty. *Otolaryngol Head Neck Surg* 2004;131(2):81.
2. Erdogan B, Tuncel A, Adanali G, et al. Augmentation rhinoplasty with dermal graft and review of the literature. *Plast Reconstr Surg* 2003;111(6):2060-2068.
3. Lipsett E. A new approach to surgery of the lower cartilaginous vault. *Arch Otolaryngol* 1959;70:42-47.
4. Kridel RW, Konior RJ. Controlled nasal tip rotation via the lateral crural overlay technique. *Arch Otolaryngol Head Neck Surg* 1991;117(4):411-415.
5. Rohrich RJ, Muzaffar AR, Janis JE. Component dorsal hump reduction: the importance of maintaining dorsal aesthetic lines in rhinoplasty. *Plast Reconstr Surg* 2004;114(5):1298-1308.
6. Hinton AE, Hung T, Daya H, et al. Visibility of puncture sites after external osteotomy in rhinoplastic surgery. *Arch Facial Plast Surg* 2003;5:408-411.
7. Hanasono MM, Kridel RWH, Pastorek NJ, et al. Correction of the soft tissue pollybeak using triamcinolone injection. *Arch Facial Plast Surg* 2002;4:26-30.
8. Constantian MB. Indications and use of composite grafts in 100 consecutive secondary and tertiary rhinoplasty patients: introduction of the axial orientation. *Plast Reconstr Surg* 2002;110(4):1116-1133.
9. Kridel RWH, Yoon PJ, Koch J. Prevention and correction of nasal tip bossae in rhinoplasty. *Arch Facial Plast Surg* 2003;5:416-422.
10. Kridel RW, Konior RJ, Shumrick KA, et al. Advances in nasal tip surgery. The lateral crural steal. *Arch Otolaryngol Head Neck Surg* 1989;115(10):1206-1212.
11. Goldman IB. The importance of the mesial crura in nasal-tip reconstruction. *Arch Otolaryngol Head Neck Surg* 1957;65:143-147.
12. Dyer WK 2nd, Yune ME. Structural grafting in rhinoplasty. *Facial Plast Surg* 1997;13(4):269-277.